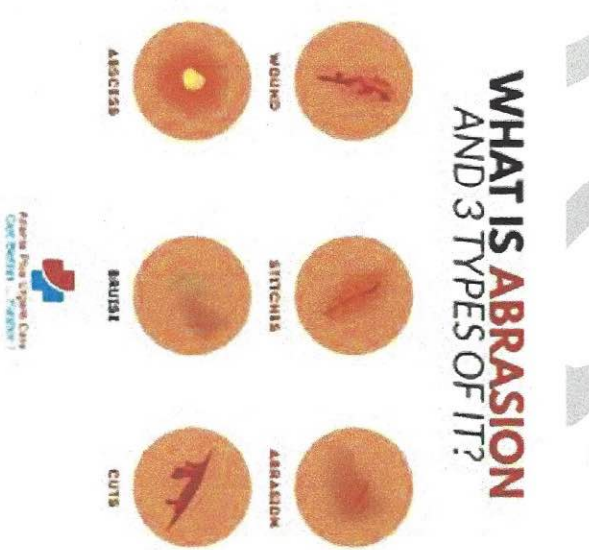


Name: Mrs. Doe  
Date of Birth: 12.03.1940  
Date of Injury: 03.04.2019

Date	Provider	Medical Facts	Comments	Page #
03.05.2019	Urgent Care	<p><b>URGENT CARE VISIT</b> This 78 year old female presents for fall: face/knee injury. <b>HISTORY OF PRESENT ILLNESS</b> Fell yesterday on some uneven ground. Fell forward onto her face. Didn't really hit her head hard but skidded on the ground and damaged the skin. No LOC. [Loss of Consciousness] No amnesia. No headache or dizziness. No nausea. No changes in vision, hearing, speech, or swallowing. No neck pain but feels stiff all over. Scraped up her face. Injured her upper teeth and her gums were bleeding. Bite felt off yesterday but feels better today. Able to chew. R [right] knee is sore and stiff. + anterior [front] abrasions. ? swelling. Pain is in the posterior [back] part of the knee. No popping or clicking of the knee. No locking or giving out. Has some other minor abrasions but no other big pain. <b>PAST MEDICAL/SURGICAL HISTORY</b> Lung dz [disease]</p>		2019_03 uc_1.pdf Pg. 1

Information is based on medical records received to date. This report is subject to change if additional documents are received.  
LAW Nurse Consulting reserves the right to amend this report with the discovery of further records.

Name: Mrs. Doe  
 Date of Birth: 12.03.1940  
 Date of Injury: 03.04.2019

Date	Provider	Medical Facts	Comments	Page #
		<p>Medications: OFEV 100mg take 1 capsule by oral route 2 times every day [For treatment of pulmonary fibrosis]</p> <p>REVIEW OF SYSTEMS:            [All noted within normal limits except]            Ears, nose, mouth, throat - Tooth pain, Bite feels off.            Psych - Feeling foggy            Integumentary - Abrasions, No - Ecchymosis [Bruises]            Musculoskeletal - Positive Joint pain, joint swelling.            ...  <b>PHYSICAL EXAM:</b>            [All within normal limits except]            Head/Face- No TMJ tx [Temporomandibular joint treatment] From with nl [normal] occlusion [arrangement of teeth]            Nose/Mouth/Throat- Upper lip is swollen and sl. [slightly] bruised. There is a small sealed laceration inside the upper lip. Teeth appear intact and solid.            Skin- There is bruising, shallow abrasions and mild tx [suspect tenderness] over the patellas</p>	<p>Abrasion- open wound</p> <p>Temporomandibular Joint- The joint near the ears, that connects the upper and lower jaws.</p>	

Information is based on medical records received to date. This report is subject to change if additional documents are received.  
 LAW Nurse Consulting reserves the right to amend this report with the discovery of further records.

Name: Mrs. Doe  
Date of Birth: 12.03.1940  
Date of Injury: 03.04.2019

Date	Provider	Medical Facts	Comments	Page #
		<p>bilat. [L.M.: as transcribed] There are also small and superficial abrasions of the face-R cheek, philtrum and upper lip. All clean and dry. No erythema.</p> <p>Musculoskeletal - Both knees no deform [suspect deformity] or edema. [swelling] No effusion. + tx over the patella bilat, and over the intra-patellar area R side. PROM without crepitation. [cracking noise in knee] No laxity [weakness] varus or valgus stress. Neg. Lachman's. Neg MacMurray's. Neg. drawer signs. [Assessment tests to identify injury]</p> <p>... DISCHARGE SUMMARY: ASSESSMENT/PLAN:</p> <ol style="list-style-type: none"> <li>1. Contusion of face, initial encounter. History suggests subluxation of the TMI which appears to have spontaneously reduced. Bite is normal now and pt. is able to chew. Upper teeth appear intact. There is no bony facial tenderness to suggest fracture. Strongly urged her to see dentist to have teeth evaluated.</li> </ol>	<p>Philtrum - midline groove between nose and upper lip Patella - knee cap</p> <p>Erythema- superficial redness of the skin</p> <p>Contusion- Damage to skin and deeper tissues, medical term for bruises.</p>	

Information is based on medical records received to date. This report is subject to change if additional documents are received. LAW Nurse Consulting reserves the right to amend this report with the discovery of further records.